

6. Madhi SA, Kwatra G, Myers JE, Jassat W, Dhar N, Mukendi CK, et al. Population immunity and Covid-19 severity with Omicron variant in South Africa. *N Engl J Med*. 2022;NEJMoa2119658. <https://doi.org/10.1056/NEJMoa2119658>

Address for correspondence: Jackie Kleynhans, Centre for Respiratory Diseases and Meningitis, National Institute for Communicable Diseases of the National Health Laboratory Service, 1 Modderfontein Rd, Sandringham, 2192, Johannesburg, South Africa; email: jackiel@nicd.ac.za

***Angiostrongylus cantonensis* in a Red Ruffed Lemur at a Zoo, Louisiana, USA**

Jessica Rizor, Ryan A. Yanez, Tuddow Thaiwong, Matti Kiupel

Authors affiliation: Michigan State University Veterinary Diagnostic Laboratory, Lansing, Michigan, USA

DOI: <https://doi.org/10.3201/eid2805.212287>

A red ruffed lemur (*Varecia rubra*) from a zoo in Louisiana, USA, was euthanized for worsening paresis. Brain and spinal cord histology identified eosinophilic meningoencephalomyelitis with intralesional adult *Angiostrongylus* sp. nematodes. PCR and sequencing confirmed *A. cantonensis* infection, indicating this parasite constitutes an emerging zoonosis in the southeastern United States.

A*ngiostrongylus cantonensis* is a parasitic metastrongyloid nematode that has a neurotropic larval stage and is endemic throughout Southeast Asia and the Pacific Islands. The rat (*Rattus* spp.) is the main definitive host and a variety of gastropods serve as intermediate hosts. In rats, infections cause no brain damage and only some pulmonary disease in severe infections. However, in aberrant hosts, including humans and nonhuman primates, larvae cause severe eosinophilic meningoencephalitis. Clinical signs are associated with migration of the larvae and the immune response to dead or dying nematodes (1).

In 1987, *A. cantonensis* nematodes were detected in rats in New Orleans, Louisiana, USA (2); in 1995, a human case of eosinophilic meningitis was reported in North America in a child from New Orleans (3). *A. cantonensis* nematodes have now become endemic in the southeastern United States, as evidenced by reports of infection in a child in Texas (4); a horse from Mississippi (5); captive Geoffroy's tamarins (*Saguinus geoffroyi*) in Alabama (6); and several animals in Florida, including a white-handed gibbon (*Hylobates lar*), an orangutan (*Pongo pygmaeus*), a white-throated capuchin monkey (*Cebus capucinus*), a red ruffed lemur (*Varecia rubra*), and a nine-banded armadillo (*Dasypus novemcinctus*) (7,8). Ingestion of infected gastropods and paratenic hosts or unwashed contaminated vegetables are proposed routes of infection for aberrant hosts.

The International Union for Conservation of Nature lists red ruffed lemurs (*Varecia rubra*) as critically endangered (9). In June 2021, a 9-year-old male red ruffed lemur from a zoo in Louisiana was humanely euthanized because of hind limb paresis and a right head tilt that worsened over an 8-day period. The lemur was housed in a troop of 5 adult lemurs in an outdoor exhibit. Various snail species are common in the enclosure, but no other lemurs were clinically affected.

A necropsy performed at the Michigan State University Veterinary Diagnostic Laboratory (Lansing, Michigan, USA) identified no gross lesions. The laboratory formalin-fixed and processed the brain, the entire spinal cord, and all major organs for histopathology. Histopathologic examination revealed multiple transverse and longitudinal sections of adult nematodes within the subarachnoid space and neuropil of the cerebellum and brainstem. Nematodes were $\approx 50\text{--}70\ \mu\text{m}$ in diameter and had a 3–4- μm thick smooth, eosinophilic cuticle and prominent lateral cords. Adult nematodes had coelomyarian musculature, and the pseudocoelom contained a reproductive tract and an intestinal tract lined by multinucleated cells with flocculent eosinophilic to brown material in the lumen (Figure). Nematodes were surrounded by hemorrhage and small numbers of eosinophils, neutrophils, macrophages, and glial cells. Several cerebellar folia were effaced by invading nematodes, hemorrhage, and inflammation. The cerebellar meninges were expanded by numerous eosinophils, fewer neutrophils, foamy macrophages, multinucleated giant cells, and lymphocytes. A representative section of thoracic spinal cord contained an identical single adult nematode in the subdural space. Another adult nematode had regionally effaced the dorsal horn in a section of lumbar spinal cord. The affected spinal cord had regional rarefaction of both gray and white

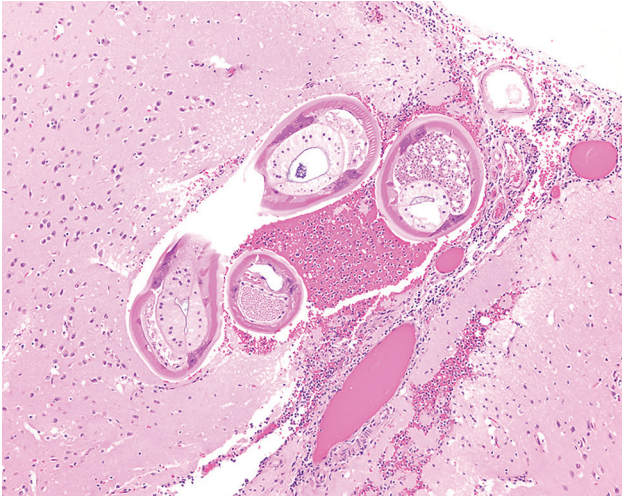


Figure. Formalin-fixed brainstem specimen from red ruffed lemur (*Varecia rubra*) infected with *Angiostrongylus cantonensis* nematodes at a zoo in Louisiana, USA. Hematoxylin and eosin stain shows adult nematodes measuring $\approx 50\text{--}70\ \mu\text{m}$ in diameter with $3\text{--}4\ \mu\text{m}$ thick, smooth, eosinophilic cuticle and prominent lateral cords. Nematodes have a coelomyarian musculature and a pseudocoelom that contains a reproductive tract and an intestinal tract, lined by multinucleated cells. Original magnification $\times 10$.

matter and marked variation in myelin sheath size. The spinal cord meninges were similarly expanded by moderate numbers of eosinophils, lymphocytes, plasma cells, and fewer eosinophils.

We suspected *Angiostrongylus* sp. nematode infection on the basis of histomorphologic findings and anatomic features of migrating nematodes. We extracted nematode DNA by using a QIAamp DNA FFPE Tissue Kit (QIAGEN, <https://www.qiagen.com>) following the manufacturer's instructions. We performed species identification by PCR on paraffin-embedded brain tissue using primers (forward 5'-TGA AAT CGT TGA AGT GGA ACC-3' and reverse 5'-GTC GCA ACC TGT ACG CTC TAC-3') that we designed specifically to amplify an $\approx 500\text{-bp}$ product of the 28S ribosomal RNA gene. Sanger sequencing of the amplicon revealed $>99\%$ similarity to *A. cantonensis* (GenBank accession no. AY292792.1), 92% to *A. vasorum* (GenBank accession no. AM039758.1), and 91% to *A. chabaudi* (GenBank accession no. KM216825.1).

In the southeastern United States, *A. cantonensis* nematodes have emerged as clinically significant parasites in mammals, including humans, causing severe neurologic disease and death. Our findings illustrate another example of a nonhuman primate succumbing to infection and should raise awareness of the potential risk for infection in endemic areas. Diagnosing *A. cantonensis* infection in a live patient is challenging because of nonspecific clinical signs,

ineffective serologic testing, and inability to detect adult nematodes in cerebrospinal fluid. Real time PCR performed on cerebrospinal fluid has detected DNA remnants of larvae in 22 of 33 human patients with eosinophilic meningitis (10). Because diagnosing and treating *A. cantonensis* infection is difficult, awareness and prevention are key. Humans and animals should only consume thoroughly cleaned vegetables and fully cooked gastropods and paratenic hosts. Persons living in affected areas can reduce risks for invasive gastropod species to become established by protecting food storage areas and local gardens from rats and gastropods.

In conclusion, the *A. cantonensis* nematode is emerging in the southeastern United States, and its range seems to be expanding. Because this parasite can infect a wide variety of mammals, including humans, both human and veterinary caretakers should remain vigilant for this zoonotic pathogen.

Acknowledgments

We thank Zoosiana in Broussard, Louisiana, and All Creatures Veterinary Hospital in New Iberia, Louisiana, for their dedication in caring for these animals.

About the Author

Ms. Rizor is a third-year doctor of veterinary medicine candidate at Michigan State University College of Veterinary Medicine in Lansing, Michigan, USA. Her main research interests are immunology and infectious diseases.

References

1. da Silva AJ, Morassutti AL. *Angiostrongylus* spp. (Nematoda; Metastrongyloidea) of global public health importance. *Res Vet Sci.* 2021;135:397–403. <https://doi.org/10.1016/j.rvsc.2020.10.023>
2. Kim DY, Stewart TB, Bauer RW, Mitchell M. *Parastrongylus* (= *Angiostrongylus*) *cantonensis* now endemic in Louisiana wildlife. *J Parasitol.* 2002;88:1024–6. [https://doi.org/10.1645/0022-3395\(2002\)088\[1024:PACNEI\]2.0.CO;2](https://doi.org/10.1645/0022-3395(2002)088[1024:PACNEI]2.0.CO;2)
3. New D, Little MD, Cross J. *Angiostrongylus cantonensis* infection from eating raw snails. *N Engl J Med.* 1995;332:1105–6. <https://doi.org/10.1056/NEJM199504203321619>
4. Al Hammoud R, Nayas SL, Murphy JR, Heresi GP, Butler IJ, Pérez N. *Angiostrongylus cantonensis* meningitis and myelitis, Texas, USA. *Emerg Infect Dis.* 2017;23:1037–8. <https://doi.org/10.3201/eid2306.161683>
5. Costa LRR, McClure JJ, Snider III TG, Stewart TB. Verminous meningoencephalomyelitis by *Angiostrongylus* (= *Parastrongylus*) *cantonensis* in an American miniature horse. *Equine Vet Educ.* 2000;12:2–6. <https://doi.org/10.1111/j.2042-3292.2000.tb01754.x>
6. Kottwitz JJ, Perry KK, Rose HH, Hendrix CM. *Angiostrongylus cantonensis* infection in captive Geoffroy's tamarins (*Saguinus geoffroyi*). *J Am Vet Med*

- Assoc. 2014;245:821–7. <https://doi.org/10.2460/javma.245.7.821>
7. Duffy MS, Miller CL, Kinsella JM, de Lahunta A. *Parastrostrongylus cantonensis* in a nonhuman primate, Florida. *Emerg Infect Dis*. 2004;10:2207–10. <https://doi.org/10.3201/eid1012.040319>
 8. Walden HDS, Slapcinsky J, Rosenberg J, Wellehan JFX. *Angiostrongylus cantonensis* (rat lungworm) in Florida, USA: current status. *Parasitology*. 2021;148:149–52. <https://doi.org/10.1017/S0031182020001286>
 9. Borgerson C, Eppley TM, Patel E, Johnson S, Louis EE, Razafindramanana J. *Varecia rubra*. IUCN red list of threatened species 2018 [cited 2018 July 5]. <https://www.iucnredlist.org/species/22920/115574598>
 10. Qvarnstrom Y, Xayavong M, da Silva AC, Park SY, Whelen AC, Calimlim PS, et al. Real-time polymerase chain reaction detection of *Angiostrongylus cantonensis* DNA in cerebrospinal fluid from patients with eosinophilic meningitis. *Am J Trop Med Hyg*. 2016;94:176–81. <https://doi.org/10.4269/ajtmh.15-0146>

Address for correspondence: Matti Kiupel, Michigan State University Veterinary Diagnostic Laboratory, 4125 Beaumont Rd, Lansing, MI 48910, USA; email: kiupel@msu.edu

Breast Milk as Route of Tick-Borne Encephalitis Virus Transmission from Mother to Infant

Jana Kerlik, Mária Avdičová, Monika Musilová, Jana Béřešová, Roman Mezencev

Author affiliations: Regional Public Health Authority, Banská Bystrica, Slovakia (J. Kerlik, M. Avdičová, M. Musilová, J. Béřešová); Slovak Medical University Faculty of Medicine, Bratislava, Slovakia (M. Avdičová); Georgia Institute of Technology, Atlanta, Georgia, USA (R. Mezencev)

DOI: <https://doi.org/10.3201/eid2805.212457>

Tick-borne encephalitis virus (TBEV) is transmitted mainly by tick bites, but humans can acquire infection through consuming unpasteurized milk from infected animals. Interhuman transmission of TBEV by breast milk has not been confirmed or ruled out. We report a case of probable transmission of TBEV from an unvaccinated mother to an infant through breast-feeding.

Alimentary outbreaks of tickborne encephalitis (TBE) have been caused by consuming unpasteurized milk from infected goats, sheep, and rarely also from cows (1). Although tick-borne encephalitis virus (TBEV) has been isolated from milk of infected animals (2–4), interhuman transmission through breast milk has not yet been established (5).

At the end of May 2020, a 29-year-old woman had temporal lobe headache, neck stiffness, muscle weakness, and her temperature increased to 38.5°C. Her condition did not improve for 3–4 days, and on May 29, she was admitted to an emergency care facility. At admission, the patient reported having a transient fever 1 week before her admission that lasted several days. Her clinical evaluation led to an initial diagnosis of a neuroinfection.

Subsequently, the patient had peripheral paresis develop in the right upper limb and paresthesia in the left hand. On the second day of hospitalization, she had a generalized seizure, low peripheral O₂ saturation of 80%, and stupor. Test results for TBEV IgM were positive for serum and cerebrospinal fluid.

Before hospitalization, the patient was breast-feeding her 8-month-old infant, including the entire period when she had clinical symptoms. On May 31, when the patient was transferred to an intensive care unit, the infant was admitted to an inpatient care unit because of fever (temperature ≤40°C) since the previous day. The infant did not show signs of meningeal irritation, and cerebrospinal fluid was negative for TBEV IgM. Therefore, the infant was discharged and started home care on June 4. Tests for detection of the TBEV RNA by reverse transcription PCR were not performed.

In the days after discharge, the temperature of the infant increased to 38°C. On June 11, the infant was evaluated in an emergency medical facility because of a low-grade fever and more prominent apathy. However, the infant was not admitted to an in-patient care unit and was discharged because the condition was not considered clinically serious and was thought to represent teething effects. However, on June 25, a serum specimen from the infant was collected at the office of a district pediatrician and tested for TBEV antibody. The test result was positive for TBEV IgM.

Cases of TBE in infants have been infrequently reported. However, the increasing number of cases reported more recently from several countries in Europe implies that TBE might be underreported and not exceedingly rare in infants (6). Some of these cases that lack a history of tick bites might have resulted from another route of transmission.